

手部肌腱损伤的修复

朱庆棠 qtzhu@qq.com

中山大学附属第一医院显微创伤手外科



中山大學

THE FIRST AFFILIATED HOSPITAL, SUN YAT-SEN UNIVERSITY

附属第一医院



内容提要

- 手部肌腱应用解剖
- 手部肌腱损伤修复
- 肌腱修复术后的康复需求

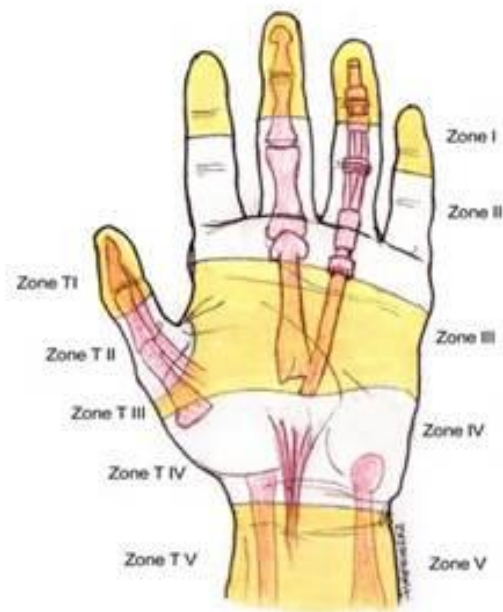
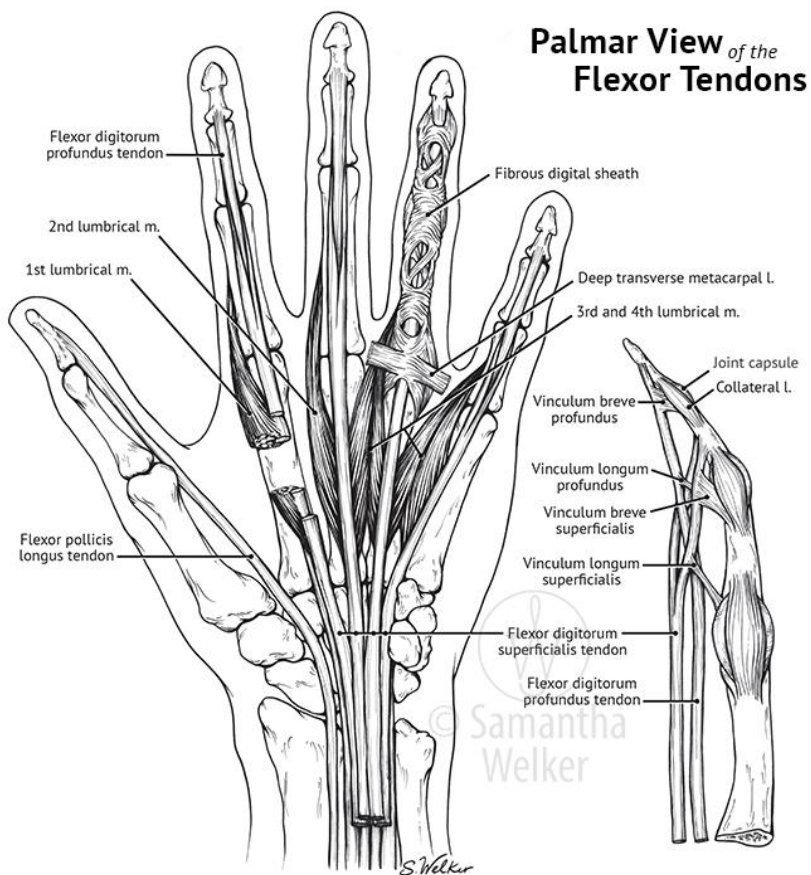


中山大學

THE FIRST AFFILIATED HOSPITAL, SUN YAT-SEN UNIVERSITY

附属第一医院

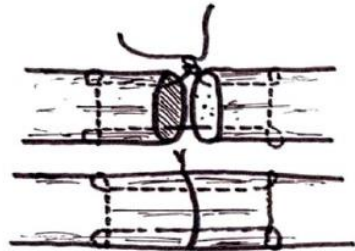
手部屈肌腱解剖特点



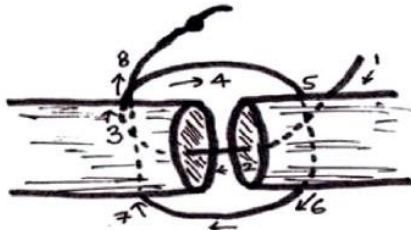
手指屈肌腱的修复



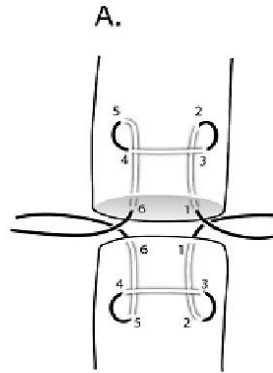
Horizontal mattress suture



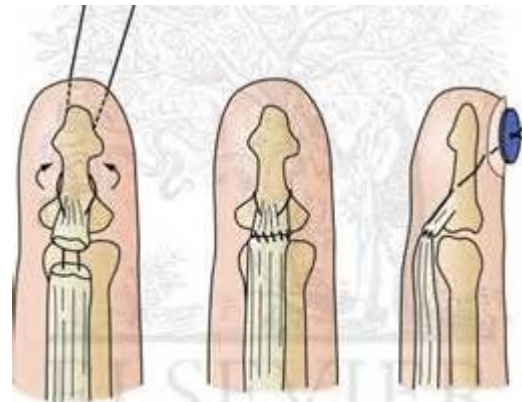
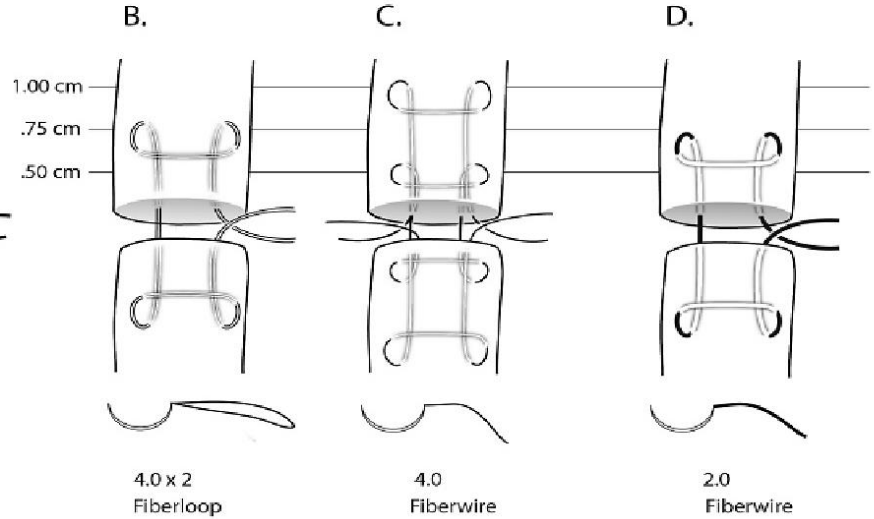
Modified Kessler stitch with single knot at repair



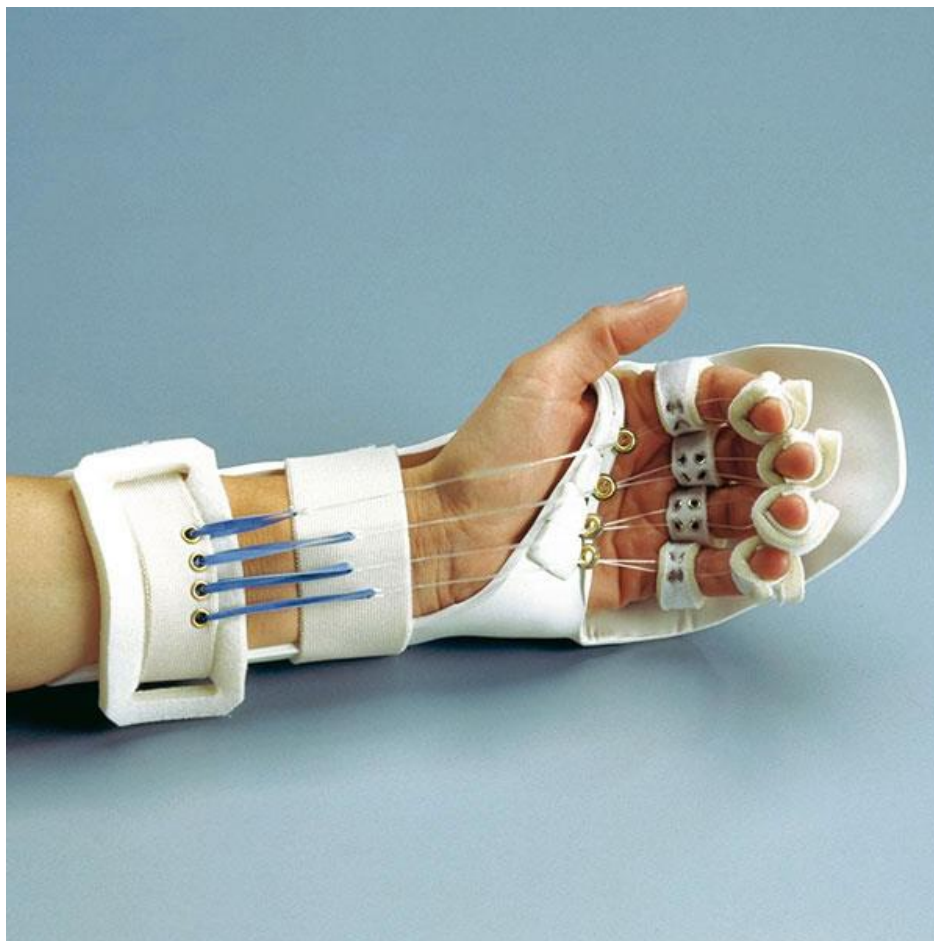
Double right angle suture



Pennington Repair

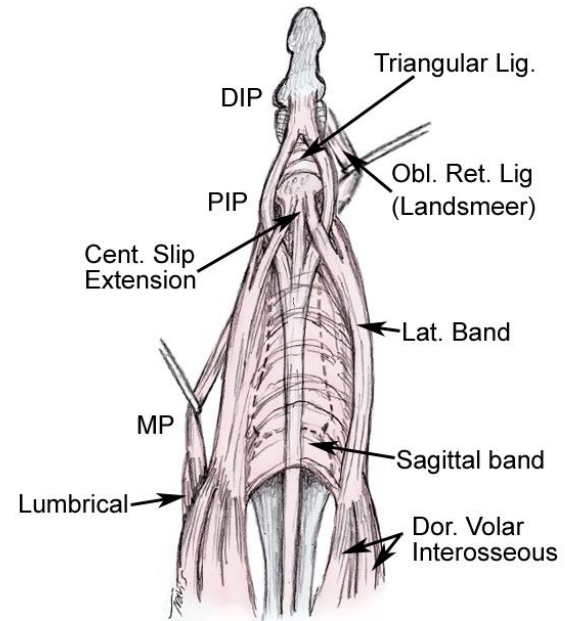
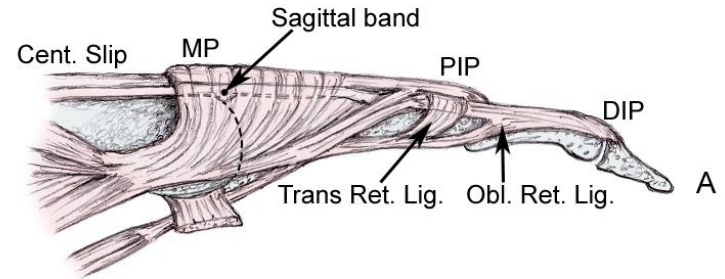
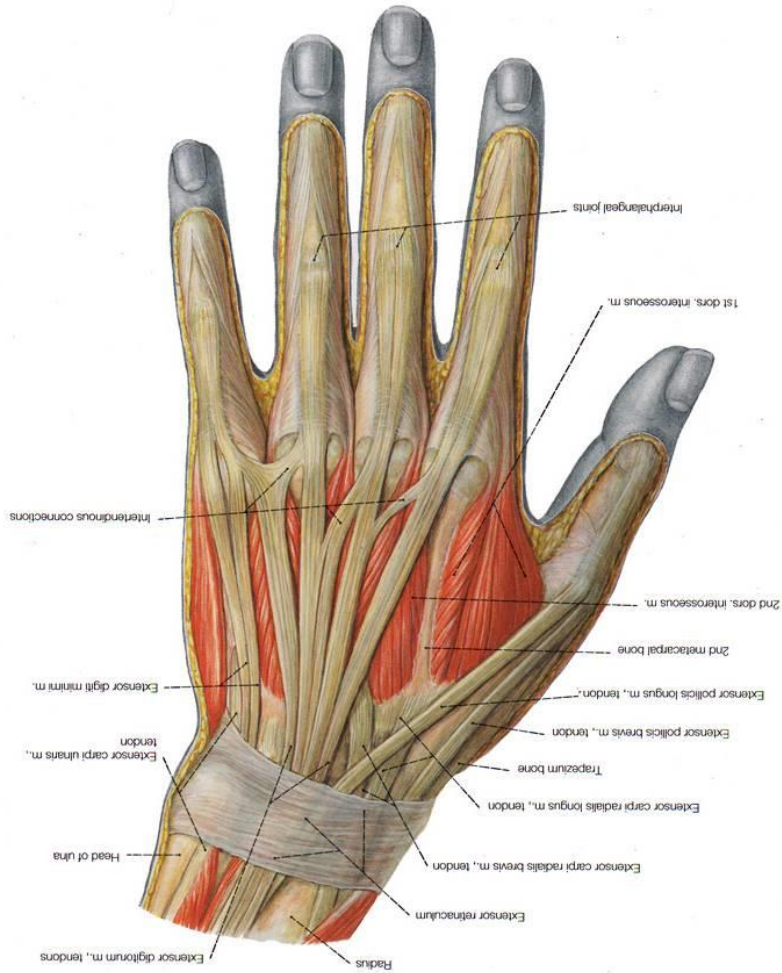


屈肌腱术后支具



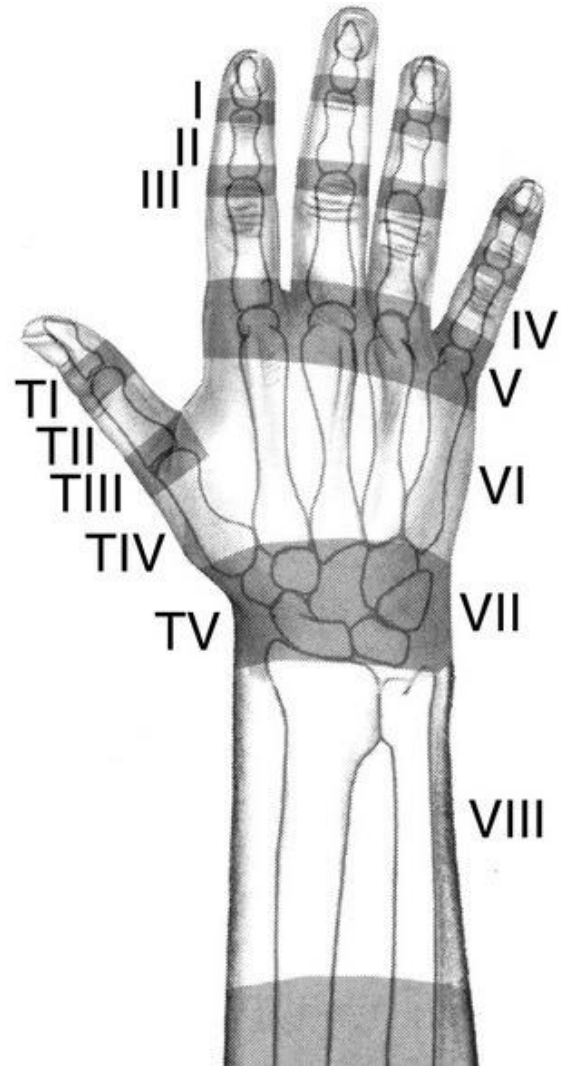
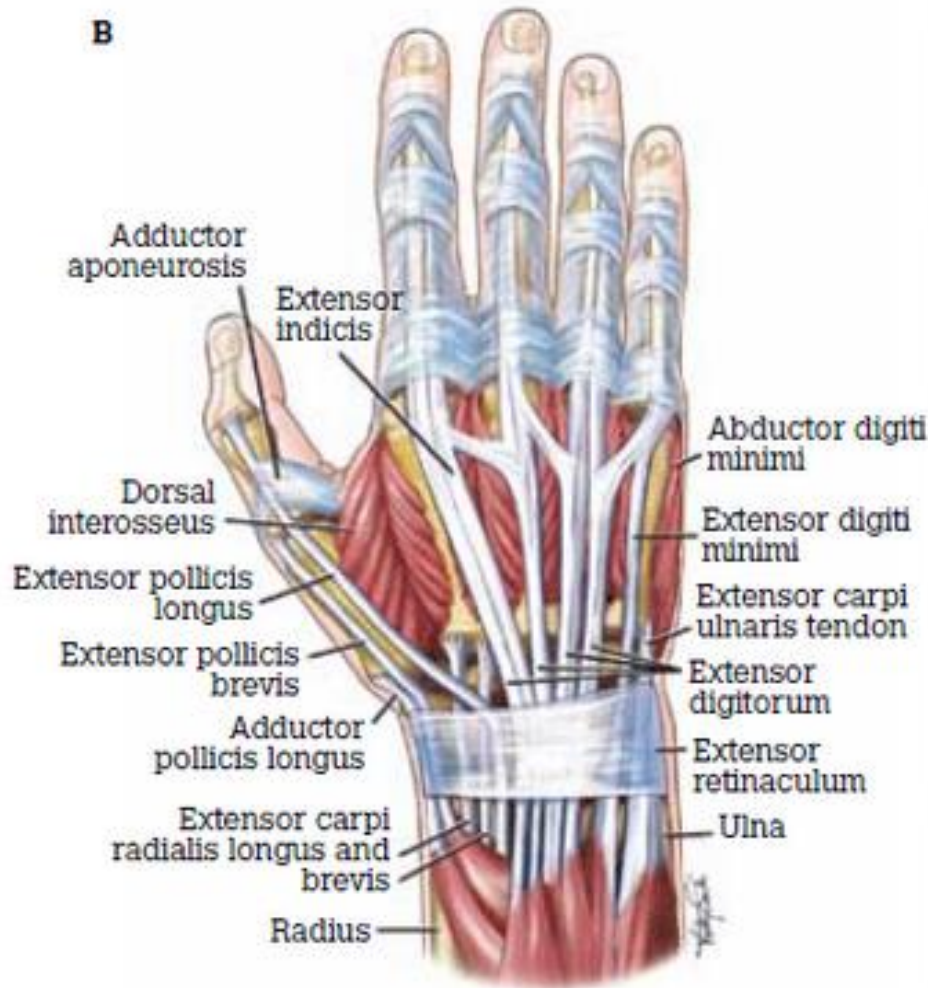
中山大学
THE FIRST AFFILIATED HOSPITAL, SUN YAT-SEN UNIVERSITY
附属第一医院

手部伸肌腱解剖特点

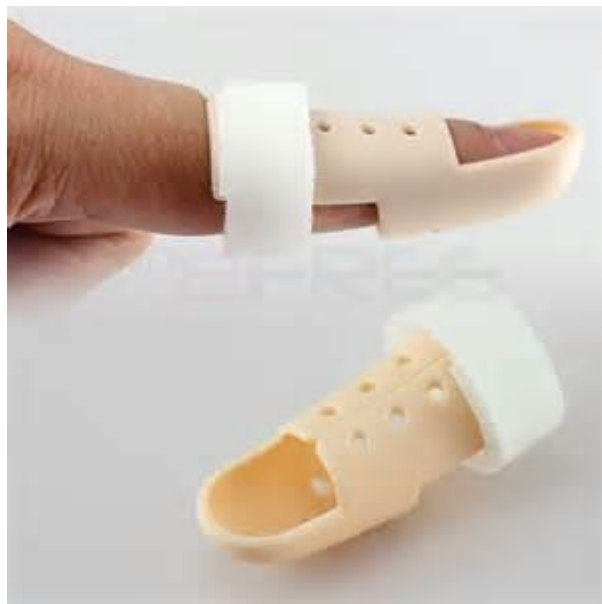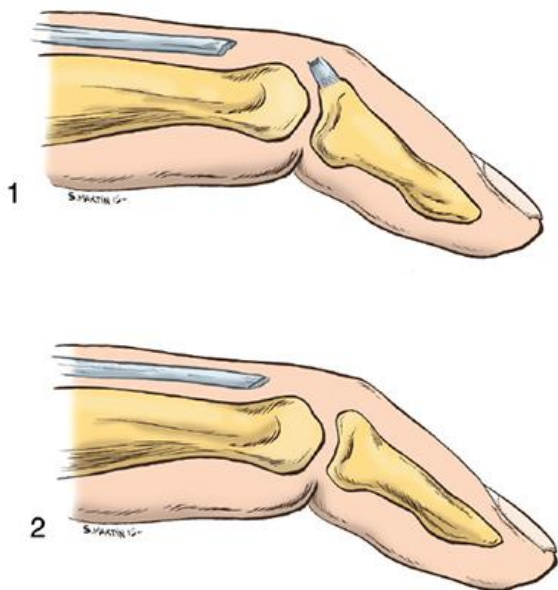


B

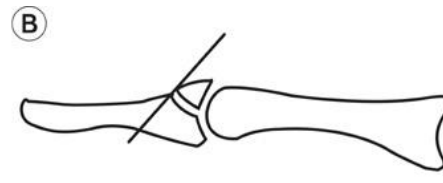

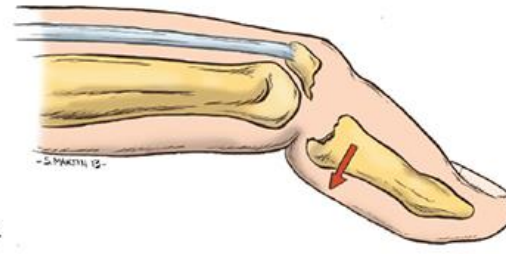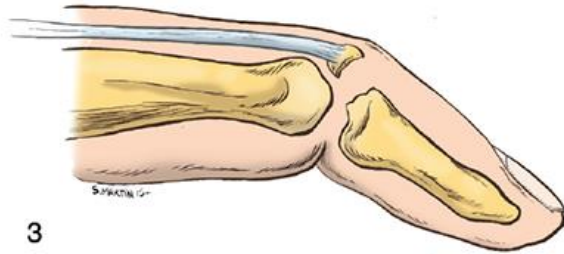
手部伸肌腱分区



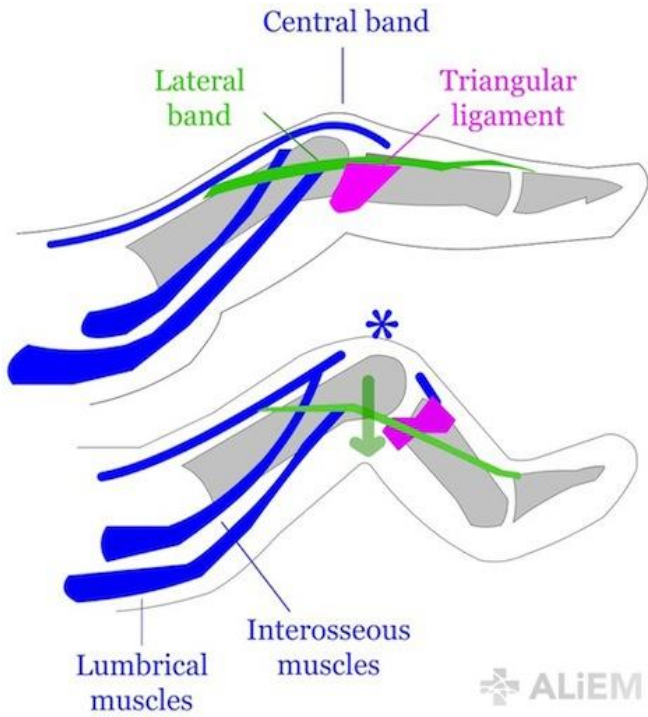
伸肌腱区损伤修复



伸肌腱区损伤修复



伸肌腱III区断裂修复



ALIEM

Modified Kessler

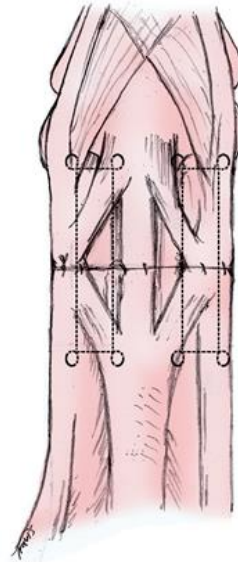
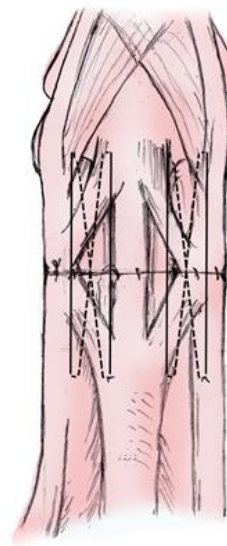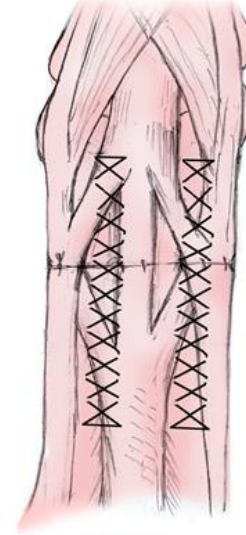


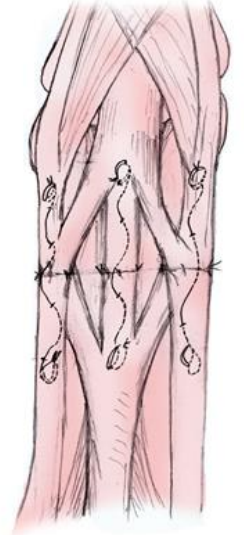
Figure-of-8



Modified Becker



6-Stranded double-loop



肌腱修复术后的康复需求

- 支具制动保护
- 保护下功能锻炼
- 消肿，防粘连



中山大學

附屬第一醫院

THE FIRST AFFILIATED HOSPITAL, SUN YAT-SEN UNIVERSITY



中山大学
THE FIRST AFFILIATED HOSPITAL, SUN YAT-SEN UNIVERSITY
附属第一医院

谢谢



2010